



Invited lecture/Scientific contribution

# Erythrocyte Sedimentation in Tubes for Preparation of Human, Equine and Canine Plasma Rich with Platelets and Extracellular Vesicles

Arko Matevž<sup>1</sup>, Schlosser Gitta<sup>2</sup>, Igljč Aleš<sup>3,4</sup>, Kruljc Peter<sup>5</sup>, Nemeč Svete Alenka<sup>6</sup>, Erjavec Vladimira<sup>6</sup>, Kralj-Igljč Veronika<sup>1,\*</sup>

- <sup>1</sup> University of Ljubljana, Faculty of Health Sciences, Laboratory of Clinical Biophysics, Ljubljana, Slovenia
- <sup>2</sup> Eötvös Loránd University, Institute of Chemistry, Department of Analytical Chemistry, Budapest, Hungary
- <sup>3</sup> University of Ljubljana, Faculty of Electrical Engineering, Laboratory of Physics, Ljubljana, Slovenia;
- <sup>4</sup> University of Ljubljana, Faculty of Medicine, Laboratory of Clinical Biophysics, Ljubljana, Slovenia;
- <sup>5</sup> University of Ljubljana, Veterinary Faculty, Clinic for Reproduction and Large Animals, Ljubljana, Slovenia
- <sup>6</sup> University of Ljubljana, Veterinary Faculty, Small Animal Clinic, Ljubljana, Slovenia

\* Correspondence: Veronika Kralj-Igljč [veronika.kralj-iglic@zf.uni-lj.si](mailto:veronika.kralj-iglic@zf.uni-lj.si)

## Abstract:

Sedimentation of erythrocytes in equine, human and canine blood was observed in tubes, intended for preparation of plasma rich with platelets and extracellular vesicles. We observed that in human blood, plasma formation started first, followed by equine blood and canine blood. All three dependencies of the length of the plasma column on time had sigmoid shape, however, the increment was greatest in equine blood. We observed higher propensity of equine blood to form erythrocyte rouleaux by light microscopy. Approximately 70-90% of haematocrit was reached by natural sedimentation of blood in all three species.

**Keywords:** Erythrocyte Sedimentation, Canine plasma, Human blood, Equine blood, Canine blood, Plasma Rich with Platelets and Extracellular Vesicles

**Citation:** Arko M, Schlosser G, Igljč A, Nemeč Svete A, Erjavec V, Kralj-Igljč V. Erythrocyte Sedimentation in Tubes for Preparation of Human, Equine and Canine Plasma Rich with Platelets and Extracellular Vesicles. Proceedings of Socratic Lectures. 2023, 8; 53-57.  
<https://doi.org/10.55295/PSL.2023.II9>

**Publisher's Note:** UL ZF stays neutral with regard to jurisdictional claims in published maps and institutional affiliations.



**Copyright:** © 2023 by the authors. Submitted for possible open access publication under the terms and conditions of the Creative Commons Attribution (CC BY) license (<https://creativecommons.org/licenses/by/4.0/>).



## 1. Introduction

Platelet rich plasma is currently being used for treatment of variety of conditions in human and animals (Troha et al., 2023). As plasma contains also extracellular vesicles, it has been referred to as plasma rich with platelets and extracellular vesicles (PVRP) (Vozel et al., 2021). PVRP is being used in human medicine in different fields e. g. in treatment of ligament and tendon injuries, chronic wounds and burns (Troha et al., 2023). Regenerative effects of PVRP can be used in maxillofacial surgery, dental medicine, bone and joint disorders, ocular surface disorders, scar revision, alopecia and otorhinolaryngology. In veterinary medicine, PVRP is being used in therapy of ligament and tendon injuries, osteoarthritis, wound healing and treatment of burns (Troha et al., 2023). In the work of Carluccio et al. (2020), intrauterine PVRP injection proved to be beneficial in barren mares with chronic degenerative endometritis (Carluccio et al., 2020).

The contents of plasma depend on the processing methods and it is of key importance to understand these processes. There is no golden standard for preparation of plasma for all purposes and for all patients and it is indicated that optimal plasma preparation should be individualized (Steiner et al., 2022). Following analysis of patients with postoperative wounds in otorhinolaryngology (Vozel et al., 2021), a mathematical model was constructed to describe enrichment of plasma with platelets and extracellular vesicles (Božič et al., 2022). In the model, the development of plasma during sedimentation of erythrocytes (the length of the column of plasma in the tube) in dependence on time was estimated based on the data on erythrocyte sedimentation rate (ESR) as measured in the clinical laboratory (Božič et al., 2022). However, during preparation of therapeutic plasma, erythrocytes sediment in tubes of different shape than those used in measuring ESR in the clinical laboratories and it is of importance to predict the sedimentation rate in the tubes where preparation of PVRP will be made. Estimation of the processes taking place in blood would enable determination of optimal time needed to sediment erythrocytes and at the same time retain as many platelets and extracellular vesicles in plasma as possible. It is therefore of interest to find a possibility of the estimation of the optimal setting of the centrifuge and time on the basis of measurement of sedimentation of erythrocytes in the tubes for preparation of PVRP in gravitational field.

It is suggested that erythrocyte sedimentation varies widely among different animal species: in canine blood, it was much faster than in ruminant blood while in canine and porcine blood, it was in between (Ohi, 1964).

Since erythrocyte sedimentation in human and different animal species might play an important role in the preparation of individualized autologous PVRP, in this work we measured sedimentation of erythrocytes in gravitational field in three blood species: human, equine and canine. In this way we studied the same processes over a wider range of parameters, to get insight into the mechanisms taking place during the sedimentation of erythrocytes.

## 2. Methods

### 2.1 Blood sampling

The study was conducted according to the guidelines of the Declaration of Helsinki, according to the applicable Slovenian governmental regulations, Animal Protection Act, The Official Gazette of the Republic of Slovenia, no. 43/2007 and no. 38/13; human blood was donated voluntarily by the author of the study.

In human, collection was established in the morning after fasting for a minimum of 12 h overnight. A G21 needle (Microlance, Becton Dickinson, USA) and 2.7 mL evacuated tube with trisodium citrate (BD Vacutainers, 367714A, Becton Dickinson, USA) were used. Equine blood was taken from a 10 years old pregnant mare of Posavec breed owned by an author. Blood was collected twice, the first time the animal was healthy and two months later, when it developed an inflammation of the hoof (thrush on the right hind foot with grade 4 lameness). Equine blood was withdrawn by a G21 needle (Microlance, Becton Dickinson, USA) into evacuated 3 ml 454334 VACUETTE® Blood Collection Tubes (Greiner Bio-One International GmbH, Kremsmünster, Austria) with trisodium citrate by a veterinarian. Canine blood was obtained from a 22 months old female dog with no record of disease into 450 ml blood collection bag (PS11150, CompoFlex® Single, CPDA-1, Fresenius Kabi AG, 61346 Bad Homburg, Germany) for transfusion. However, blood was not used for transfusion up to the expired time and would be discarded. Four aliquots (volume 3 mL) of blood

were squeezed through a plastic tube into empty test tubes previously wetted by phosphate- and citrate-buffered saline.

### 2.2 Determination of haematocrit

After sedimentation of erythrocytes in human and in equine blood, plasma was collected and the remaining sediment was gently mixed by turning it upside down. Haematocrit was determined by centrifugation of the sample at  $2000 \times g$  for 10 minutes in the Centric 400R centrifuge (Domel, Železniki, Slovenia), in the same tubes. It was assumed that at this setting all the plasma was pushed up above the erythrocytes. The length of the erythrocyte column was measured by a ruler and the proportion of the length of the erythrocyte column with respect to the length of the column of the whole blood was taken as the haematocrit.

### 2.3 Measurement of sedimentation of erythrocytes in gravitational field

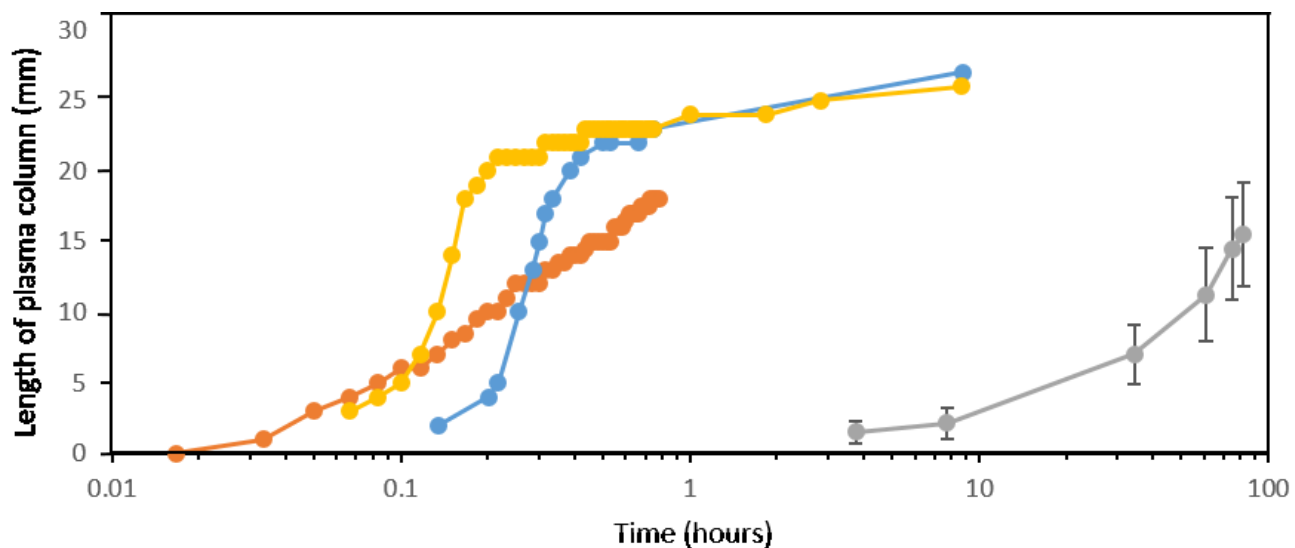
Tubes with blood were put in the vertical position at room temperature, erythrocytes were allowed to sediment and plasma to form. The descent of the level of erythrocytes (the length of the plasma column) was measured with a ruler. Time in seconds was measured by a stopwatch. In human blood, one tube of blood was measured, in equine blood, two samples of blood from the same animal were observed one month apart and in canine blood, four tubes from a single animal were observed simultaneously.

### 2.4 Imaging of erythrocytes

Images of human, equine and canine erythrocytes were obtained by a light microscope Nikon Eclipse TE2000S inverted phase contrast microscope (Nikon Instruments Inc., Tokyo, Japan) with CCD 512 Digital Camera System SPOT BOOST (Visitron Systems, Puchheim, Germany).

## 3. Results

In human blood, plasma formation started first, followed by equine and canine blood (Figure 1). All three dependencies of the length of the plasma column on time indicated sigmoid shape, however, the increment was greatest in equine blood, as it has highest propensity to form erythrocyte rouleaux.



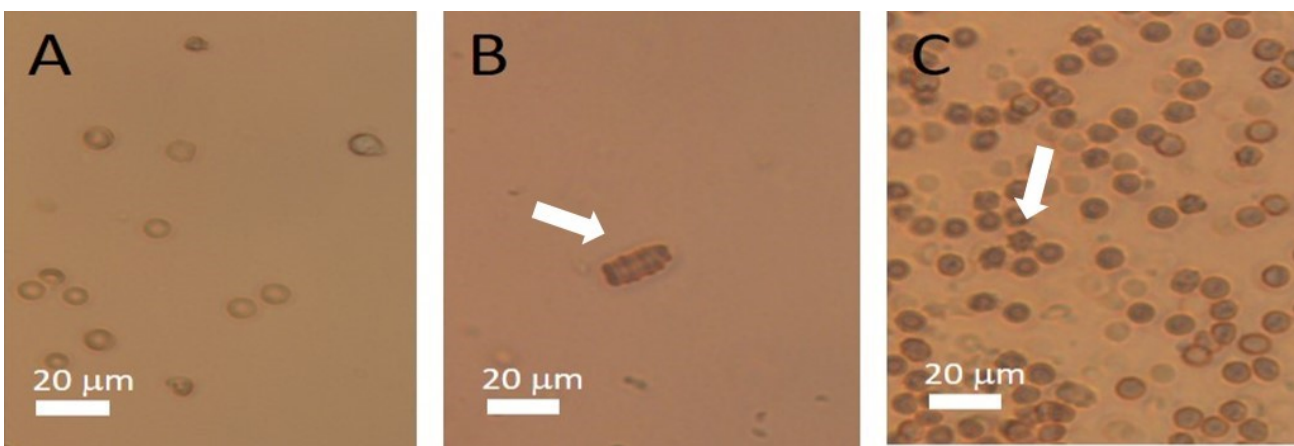
**Figure 1.** Erythrocyte sedimentation curve of equine (blue and yellow markings), human (orange markings) and canine (grey markings) blood. In the canine blood, the dots represent the average of 4 measurements. Bars represent standard deviations.

Human blood had higher haematocrit than animal blood (Table 1). When percentage of haematocrit was calculated, there were large differences in the percent of haematocrit that was reached by natural sedimentation in gravitational field.

**Table 1.** Comparison of haematocrit reached in human, equine and canine blood

Species of blood	Hematocrit	Percent of hematocrit reached by spontaneous sedimentation
Human	0.45	63
Equine	0.34	96
Canine	0.25	52

**Figure 2** shows light microscope images of erythrocytes of all three species. Discocyte shape of erythrocytes prevailed in human blood (Figure 2A). In equine blood, erythrocytes organized in a rouleau (Figure 2B, white arrow). In canine blood, echinocytes (Figure 2C, white arrow) and ghosts (transparent cells, Figure 2C) were observed.



**Figure 2.** Light microscope image of human (A), equine (B) and canine (C) erythrocytes. On image B, there is a rouleau of stacked up equine erythrocytes (white arrow). On image C there are some echinocytes (white arrow).

#### 4. Discussion

We have measured the velocity of sedimentation of erythrocytes in three types of blood: human, equine and canine. In human blood we stopped the measurement when we observed no more changes for more than one hour, while in canine blood this time was more than 6 hours. However, the length of the erythrocyte column reached the estimated hematocrit value only to a certain extent. To estimate the hematocrit, we sedimented erythrocytes in the centrifuge by choosing the settings so that all the plasma was pushed above the erythrocytes.

We have observed that the shape of the velocity/time curve was sigmoidal in all three species, with different increments. In equine blood, the increment was the greatest and the curve reached the plateau. In contrast, in human and in canine blood, the sedimentation stopped before the plateau was reached, yet the sediment still contained plasma which could be squeezed out by centrifugation. As during sedimentation of erythrocytes plasma is pushed up, the process is slowed down when erythrocytes are settled. It seems that movement and organization of erythrocytes during sedimentation is key in development of the flow of particles. As erythrocytes are denser and larger than other particles, they are pushed down by the systemic centrifugal force. In order to enable movement of erythrocytes, plasma makes space by moving in the opposite direction. This is made more effective by redistribution of erythrocytes to form channels. As the centrifugal force is proportional to the distance between the axis of the centrifuge rotor and the position of the particle in the tube, it is the greatest at the bottom of the tube and the flow of plasma upwards is the greatest at the early phases of the sedimentation. While the erythrocytes settle at the bottom and closely pack,



they cease to generate the plasma flow. Also, it could be expected that a large mass of erythrocytes (higher hematocrit) would create more obstacles for the movement of plasma upwards and decrease the increment of the sigmoid curve.

Sedimentation of erythrocytes in different animal species was a subject of interest already in the past. In a thorough work of Ohi (1964) presents a series of experiments on different species (horses, pigs, dogs, cattle and goats) to obtain the respective sedimentation curves. In that work, the sedimentation curves were grouped in five types: vertical, steep sloped, gentle sloped, sloped straight line and horizontal straight line. In equine blood, vertical curve type prevailed, in porcine blood there were steep sloped, gentle sloped and straight line types, in canine blood, the shapes were of steep sloped, gentle sloped, straight line and horizontal straight line types. In ruminants like cattle, sheep and goats, horizontal straight line type prevailed. According to Ohi, human and equine erythrocyte sedimentation curve obtained in this work could be considered vertical while canine sedimentation curve can be considered straight line type.

In the work of Fabry (1987), sigmoid or S-shaped erythrocyte sedimentation curve by exposing a shift to the right is explained in terms of increasing erythrocyte concentration; for higher hematocrit, the delay of the initial phase increases and the slope in the following phase decreases; at higher hematocrit, the shape of the curve is similar to sloped straight line and horizontal straight line of the classification of Ohi, 1964. In our samples, the increment of the curve in human which had highest hematocrit, was smaller which agrees with the above. However, this blood started to sediment first (Figure 1).

In a horse, we made two measurements. In the first measurement the horse was healthy while in the second, 2 months later, it developed a local infection. We observed that the curve of blood subjected to the infection was shifted to the left (shorter time) but retained the increment.

Human and equine blood were fresh while canine blood was from an expired transfusion bag, taken a month before the measurement took place. Sedimentation of erythrocytes in this blood was considerably slower and it took more than two days to approach its final value. It should also be taken into account that the samples were not handled equally which could have an important impact on the results. Human blood was transported from the clinical laboratory to the facility where the observation took place while equine blood was measured at the place of blood acquisition.

**Funding:** Authors acknowledge support from ARRS, grants P2-0232, P3-0388, J2-4447, J3-3066 and National Research, Development and Innovation Office (Hungary) SNN 138407.

**Conflicts of Interest:** The authors declare no conflict of interest.

## References

1. Božič D, Vozel D, Hočevar M, et al. Enrichment of plasma in platelets and extracellular vesicles by the counterflow to erythrocyte settling. *Platelets*. 2022; 33: 592-602. DOI: 10.1080/09537104.2021.1961716.
2. Carluccio A, Veronesi MC, Plenteda D, Mazzatenta A. Platelet-rich plasma uterine infusion and pregnancy rate in barren mares with chronic degenerative endometritis. *Pol J Vet Sci*. 2020; 23: 431-438. DOI: 10.24425/pjvs.2020.134688.
3. Fabry TL. Mechanism of erythrocyte aggregation and sedimentation. *Blood*. 1987; 70: 1572-1576.
4. Ohi S. Studies on species variation of blood sedimentation in domestic animals. Variation of erythrocyte sedimentation curve. *Nihon Chikusan Gakkaiho* 1964; 35: 131-134.
5. Steiner N, Vozel D, Urbančič J, et al. Clinical Implementation of Platelet- and extracellular vesicle-rich product preparation protocols. *Tissue Eng Part A*. 2022; 28:770-780. DOI: 10.1089/ten.TEA.2022.0024.
6. Troha K, Vozel D, Arko M, et al. Autologous platelet and extracellular vesicle-rich plasma as therapeutic fluid: A review. *Int J Mol Sci*. 2023; 24: 3420. DOI: 10.3390/ijms24043420
7. Vozel D, Božič D, Jeran M, et al. Autologous platelet- and extracellular vesicle-rich plasma is an effective treatment modality for chronic postoperative temporal bone cavity inflammation: Randomized controlled clinical trial. *Front Bioeng Biotechnol*. 2021; 9: 677541. DOI: 10.3389/fbioe.2021.677541